

A rare case of Giant Cell Tumor of Distal Ulna

Soham R Chachcha¹, Ramavtar Saini¹, Anand Yadav¹

Abstract

Background: Giant Cell tumor has a reported incidence of 30% in Indian population out of which only 10% cases occur in adults more than 65 years of age. Distal Femur and proximal Tibia are the most common sites followed by distal Radius. Distal Ulna Giant cell tumor is a rare presentation.

Methods: There are no clear-cut guidelines for treatment of Giant Cell Tumor. The treatment of choice in case of Giant Cell Tumor usually is wide block resection of tumor, and to prevent recurrence adjuvant procedures can be used such as cryotherapy, phenol, cementing and bone grafting and burring. We used the en bloc resection method.

Results: After the en bloc resection of the tumor, the patient had relief in pain and the range of motion at wrist joint was restored.

Conclusion: Giant Cell tumor of distal Ulna is a rare entity and it is even rarer in Geriatric population. It can be treated with en bloc resection.

Keywords: Distal, Ulna, Giant Cell, Tumor, Geriatric.

Introduction:

Giant Cell tumor has a reported incidence of 30% in Indian population out of which only 10% cases occur in adults more than 65 years of age. Distal Femur and proximal Tibia are the most common sites followed by distal Radius [1]. Distal end epiphysis of the ulna is an uncommon site for primary bone tumors reported incidence being 0.45% to 3.2% [2]. Modality of treatment includes resection of the tumor along with different adjuvant therapies to prevent recurrence. The adjuvant therapies vary with surgeon's choice. The usual methods implemented are curettage along with burring or phenol or cryotherapy. If the bone deficit is huge, cementing and bone grafting are usually used. We here report a case of

Giant Cell Tumor (GCT) of distal Ulna in a geriatric patient. The goal of treatment is to resect the tumor cells completely along with reduction in chance of recurrence.

Case report:

A 65-year-old female who is currently a homemaker, came to Out Patient Department of Geetanjali Medical college with the chief complain of pain and gradually increasing swelling on her Right wrist on ulnar aspect in March 2018. She was asymptomatic before 3 months when she gradually developed swelling over the distal ulnar aspect of the forearm. She presented with restricted range of motion at the wrist joint with radial deviation of the hand. Patient had no history of weight loss or decreased appetite. On physical examination the swelling was of the size of 7cm X 4cm. The skin overlying the swelling was normal without any pigmentation or redness. Skin was freely mobile over the bony hard swelling. The

swelling was diffusely tender. An X-ray of right wrist with forearm was done in AP and Lateral Views and the swelling was found to be a single, expansile, osteolytic with cortical thinning and appeared multi lobulated without any periosteal reaction. Considering patients age and presentation the proposed differential diagnosis was round cell tumor, aneurysmal bone cyst, plasmacytoma and metastasis. Blood examination reports along with plasma electrophoresis study and urine routine micro turned out to be within normal limits for her age. Other X-rays included chest X-ray, Lumbo-sacral spine X-ray and pelvis with both hips X-ray. Patient had a primary scoliotic curve on the right side with partial collapse of L1 vertebra in lumbosacral X-ray with no other pathological findings. Patient had calcified Guinee worm near right hip joint in Pelvis X-ray. A CT for thorax was also done to rule out secondaries. MRI of the swelling showed expansile lytic lesion involving distal ulna measuring 7cm X 3.6cm. A FNAC was

¹Department of Orthopaedics, Geetanjali Medical College and Hospital Udaipur.

Address of Correspondence

Dr. Soham R Chachcha,
Department of Orthopaedics Geetanjali Medical College and Hospital, Eklingpurachauraha, Udaipur, RAJASTHAN 313001
Email: chacha_soham@yahoo.co.in

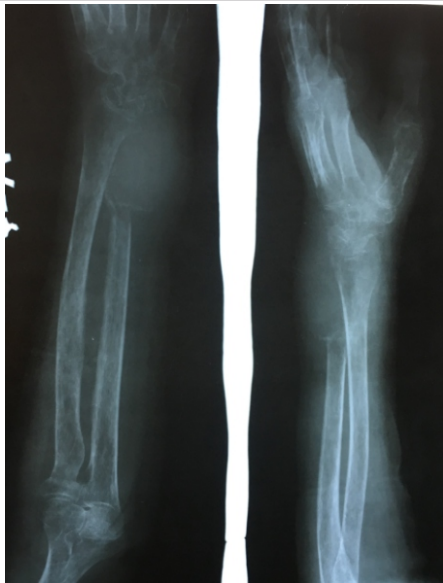

Figure 1: Pre-Op X-ray Of the Patient

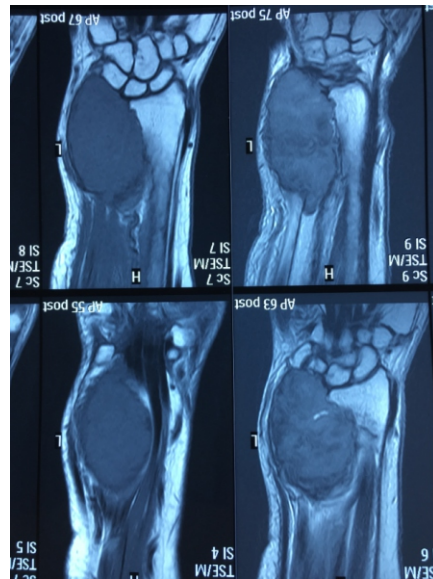


Figure 2: T2W MRI Image of the Patient

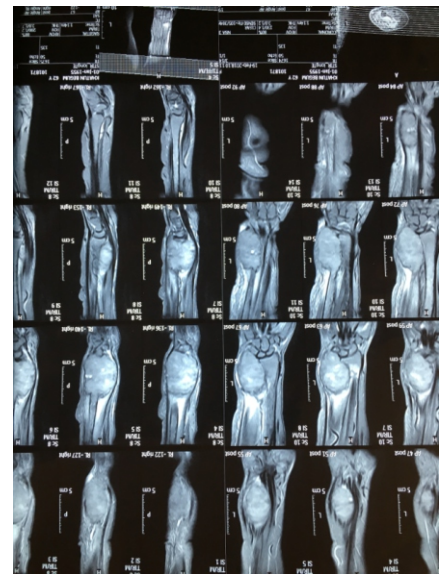


Figure 3: STIR MRI Image of the pathological Site

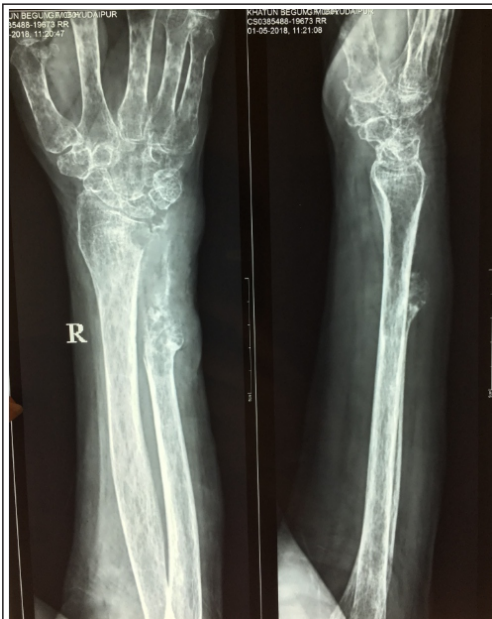

Figure 4: Post-Op X-ray Of the Patient

performed previously by a surgeon in another institute which was inconclusive. Having ruled out other possible sites for metastasis it was taken that the lesion was benign. A biopsy was performed to make an accurate diagnosis. Histology revealed benign osteoclastoma i.e. Giant Cell Tumor of distal Ulna. On the basis of clinical and radiological signs it could be graded as Enneking Type 3 (Benign). Different treatment options were considered with the patient by surgical team. Finally, en

bloc resection was planned. Ulnar approach was taken and a plane was made between Flexor carpi radialis and Extensor carpi ulnaris. En bloc resection of the tumor along with some part of healthy bone was done. Ulna shaft was stabilized by the surrounding soft tissue sleeve. Wound was closed in layers and a drain was fixed in the wound. All the sutures were removed on 15th post-op day. Stitch line was clean and healthy. Patient was relieved of pain and the supporting below elbow slab was removed and the wrist joint was mobilized. We have two months of follow up of the patient and she has no fresh complaints. X-ray of local part along with chest X-ray were also done as a part of follow up and there were no positive findings.

Discussion:

Giant Cell tumor is a rare and essentially a benign tumor [3] and occurrence in Distal Ulna is further rare. Cooney et al[4] achieved excellent results in 6 out of 8 patients treated with en bloc excision of distal ulna without reconstruction and concluded that routine reconstruction of the osseous defect is not necessary after en bloc

resection of a neoplasm of the distal end of the ulna. We had to proceed with classic darrach resection. Long-term results of the Darrach’s procedure are notpredictable [5] so we plan to follow up the patient for coming years. The demands of our patient were low and she was more than satisfied with the choice of treatment as she could return back to her routine without any pain.

Conclusion:

Giant Cell tumor of distal Ulna is a rare entity and it is even rarer in Geriatric population. En Bloc resection can be considered as a choice of treatment in patients with low functional demands.

References

1. Dr Ajay Puri, Dr. M. G. Agarwal and Dr. DinshawPardiwala in 'Current concepts in bone and soft tissue tumors' Chapter 6 Giant Cell Tumor Of Bone Page: 53-63.
2. Goldenberg RR, Campbell CJ, Bonfiglio M. Giant-Cell tumor of bone. An analysis of two hundred and eighteen cases. J Bone Joint Surg Am 1970;52:619-64.
3. D. J. McDonald, F. H. Sim, R. A. McLeod, and D. C. Dahlin, "Giant-cell tumor of bone," Journal of Bone and Joint Surgery. Series A, vol. 68, no. 2, pp. 235–242, 1986.
4. Cooney WP, Damron TA, Sim FH, Linscheid RL. En bloc resection of tumors of the distal end of the ulna. J Bone Joint Surg Am [Internet]. 1997 Mar [cited 2015 Aug 8];79(3):406–12. Available from: <http://www.ncbi.nlm.nih.gov/pubmed/9070531>.
5. B. J. Gainor and J. Schaberg, "The rheumatoid wrist after resection of the distal ulna," Journal of Hand Surgery, vol. 10, no. 6 I, pp. 837–844, 1985.

Conflict of Interest: NIL

Source of Support: NIL

How to Cite this Article

Chachcha S R, Saini R, Anand Yadav A. A rare case of Giant Cell Tumor of Distal Ulna. Journal of Clinical Orthopaedics Jan-June 2018; 3(1):22-24