Broken bone marrow biopsy needle: a case report

Deepak kumar[1], Praveen Sodavarapu[1]

Abstract

Introduction: Bone marrow biopsy is a routinely done procedure with minimum risks and complications. Here we report a case of broken bone marrow biopsy needle that occurred in a 31 year old male during one such procedure

Case report: A 31 year old male diagnosed with B Cell Acute Lymphoblastic Leukemia since 3 years who received the complete course of chemotherapy presented to the medicine department with complaint of thigh pain since 1 month. Positron Emitted Tomography guided percutaneous bone marrow aspiration and biopsy from the left femur was done. However while removing it, the patient gave a sudden movement following which the bone marrow biopsy needle broke with the distal portion remaining embedded around 3 cm deep to the skin within the muscles. A non-contrast Computed tomography scan was performed and removal in operating room under C-arm guidance was done. Post operatively there were no complaints and follow-up after 1 and 3 months was uneventful.

Conclusion: Breakage of biopsy needle, although rare, have been reported in few instances and awareness of the possibility of such adverse effect is requisite to avoid them. Usage of good quality needles, adequate anaesthesia or sedation when needed, and supervision by the experienced personnel when technical difficulty is anticipated can help in preventing such complications. Keywords: broken bone marrow needle, broken biopsy needle.

Keywords: broken bone marrow needle, broken biopsy needle.

Introduction

Bone marrow biopsy is a routinely done procedurewith minimum risks and complications, performed either onan outpatient basis or during the hospitalization and useful in diagnosing malignancies and other haematological disorders. Proper technique and adequate precautions during the procedure are necessary to avoid commonly associated complications such as haemorrhage and infection. Device failure such as breakage of biopsy needle is a rare complication. Here we report a case of broken bone marrow biopsy needle that occurred in a 31 year old male during one such procedure.

[1]Department of Orthopaedics, Post Graduate Institute of Medical Education and Research, Sector 12, Chandigarh 160012, India.

Address of Correspondence
Dr. Praveen Sodavarapu,
Department of Orthopaedics, Post Graduate Institute of Medical Education and Research, Sector 12, Chandigarh 160012, India
Email: praveen.omc.2k8@gmail.com

Case Report

A 31 year old male diagnosed with B Cell Acute Lymphoblastic Leukemia since 3 years who receiving the complete course of chemotherapy presented to the medicine department with complaint of thigh pain since 1 month. After the relevant investigations including a PET (Positron Emitted Tomography) scan which showed increased uptake in both femur, the patient was advised to undergoa PET guided percutaneousbone marrow aspiration and biopsy from the left femur. After placing the patient in supine position, the part was prepped and draped in a sterile fashion.2% lignocaine was utilized for superficial and deep local anaesthesia. Under PET guidance, bone marrow biopsy needle was advanced into the proximal femur.The inner stylet was removed, and the hollow needle was slowly advanced into the bone marrow by small rotatory movements.However while removing it, the patient gave a sudden movement followingwhich the bone marrow biopsy needle broke with the distal portion remaining embedded around3 cm deep to the skin within the muscles. A non-contrast CT (computed tomography) scan was performed to determine the exact location of the broken fragment (Fig, 1) and planned for removal in operating roomunder C-arm guidance.The anteroposterior and lateral views were utilised to localise the fragment and a skin incision was given. After soft tissue dissection, the needle fragment was found and removed and incision was closed in layers (Fig 2A and 2B). Post operatively there were no complaints and the sutures were removed after 2 weeks. Follow-up after 1 and 3 months was uneventful.

Discussion

Bone marrow aspiration and biopsy is an

Figure 1: ???

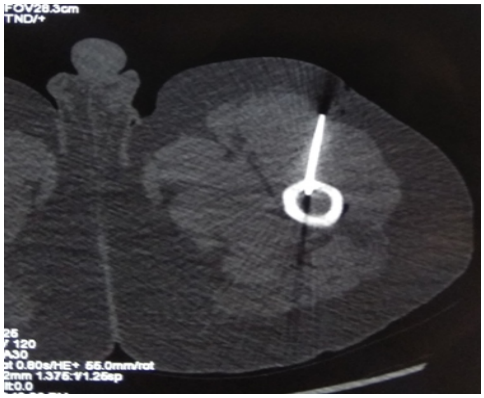

Figure 1: ???

Figure 1: ???

important diagnostic tool in clinical practice. It is considered to be a safe procedure but not completely a risk free procedure. A retrospective postal survey[1] of adverse events associated with bone marrow aspiration biopsy between 1995 and 2001 in Britain revealed 26 adverse events among 54,890 biopsies and 7 needle-related incidents involving breakage. Bain et al[2] reported that only 17 out of 13,506 patients encountered complicationsincluding 2 cases of needle breakage requiring removal in 1 patient. Similar surveys[3,4]revealed 31 adverse events in a total of 39,582 procedures,with haemorrhagebeing the most common and themost serious complication and no reports of device failure.

Complications related to broken needles are less frequentlyreported. However, it is likely that these mightbe regarded as sufficiently less that they are underreportedin comparison with the more common complications likehaemorrhage and infection. The biopsy should be performed under proper anaesthetic cover with particular attention given to infiltration of theperiosteum. Also sedation must be considered in anxious and young patients or in cases where technical difficulty is expected 5]. Autoclaved reusable needle should be avoidedand a good quality pre sterilized disposable needle should be used. Anxiety, pain, poor quality needles and an inexperienced doctor may contribute to the occurrence of such incidents, even though they constitute a minor number.In our case, retrieval was necessary as the broken needle fragment was large and was projecting around 7cm from the surface of the bone. Shaikh et al[6]described a technique of removing a broken needle fragment using a larger-bore biopsy needle passed over and through the retained,fractured needle under a CT fluoroscopic guidance which can obviate the need for an open surgicalretrieval.

Conclusions

Bone marrow aspiration and biopsya relatively safe procedure associatedwith few risks and complications. Breakage of biopsy needle, although rare, have been reported in few instances and awareness of the possibility of such adverse effect is requisite to avoid them. Usage of good quality needles, adequate anaesthesia or sedation when needed, and supervision by the experienced personnel when technical difficulty is anticipated can help in preventing such complications.

References

1. Bain BJ. Bone marrow biopsy morbidity and mortality. Br J Haematol 2003;121:94951.
2. Bain BJ. Bone marrow biopsy morbidity and mortality: 2002 data. Clin Lab Haematol 2004;26:315–18
3. Bain BJ. Bone marrow biopsy morbidity:review of 2003. J ClinPathol 2005;58:269-72
4. Bain, Barbara J. "Morbidity associated with bone marrow aspiration and trephine biopsy-a review of UK data for 2004."Haematologica 91.9 (2006): 1293-1294.
5. Hjortholm, Nikolaj, et al. "Strategies of pain reduction during the bone marrow biopsy." Annals of hematology 92.2(2013): 145-149.
6. Shaikh H, Thawani J, Pukenas B. Needle-in-needle technique for percutaneous retrieval of a fractured biopsy needle during CT-guided biopsy of the thoracic spine. IntervNeuroradiol. 2014;20(5):646–9.

Conflict of Interest: NIL
Source of Support: NIL

How to Cite this Article

Kumar D, Sodavarapu P. Broken bone marrow biopsy needle: a case report. Journal of Clinical Orthopaedics Jan-June 2019; 4(1):31-32