Review
Journal of Clinical Orthopaedics 2019 Jan-June;4(1):22-29

A method of Patient positioning which aids in reduction of Multi-directionally unstable Gartland Type 4 fractures Supracondylar Humerus fracture with review of literature

Arvind Janardhan Vatkar, Sanjay Dhar, Sachin Kale, Neeraj Bijlani

Abstract

This study is to report a novel method of positioning of patient to reduce and fix supracondylar humerus fractures. Method- 4 patients with Displaced Gratland type 4 fractures were treated in between 2017 to 2018. The patient after giving GA, was placed on a inverted OT table arm-rest, which is slid below the chest. The proximal half part of shaft humerus is supported on the arm-rest. The rod of side arm-rest is situated in the opposite side axilla of the patient. The supported part of arm is strapped to the side armrest and the distal part of elbow is kept free for manipulation and insertion of K wires. C arm turned to AP and lateral positions to take shoots. Conclusion- Closed Reduction pinning of Multi-directionally unstable Gartland Type 4 fractures can be done safely and effectively in this novel method by using a side arm stand.

Keywords: Supracondylar humerus fractures, Multi directionally unstable , position of patient, K wire technique, instability

Introduction

Most common pediatric elbow fractures are at the supracondylar humerus level which comprises of 3% of all fractures in children. Supracondylar Humerus fractures (SHF), are classified based on the displacement of the distal fragment of humerus as Extension and flexion type. Extension type is further classified by Gartland [1].

Extension type of fractures comprise upto 97% of SCHF. Flexion type comprise of the rest 3%. Closed reduction and K wire fixation is a standard procedure of treatment in displaced Supracondylar humerus fracture[2].

Leitch et al proposed a extended new classification of Type 4 Gartland SCHF in which the periosteal hinge is circumferentially disturbed, making it unstable both in flexion and extension of elbow. This type of fracture can be due to primary high energy injury or due to iatrogenic aggressive manipulation of fragments in extension type SHF [3]. They pose a surgical challenge which needs modifications from conventional way of reduction of fracture fragments[3,5 3,5].

Surgery of SHF is divided into 3 steps [4]

1. Positioning of patient on operation table.
2. Reduction of Fracture Fragments.
3. Percutaneous K wire pinning of fracture site.

We had pondered upon the positioning of patient on OT table to make the surgery easier and convenient for the surgeon. If positioning of patient is done properly, reduction and K wire pinning can become more easy and efficient.

We studied an innovative and reproducible method of patient positioning for reduction and K wire pinning of Garland Type 4 SHF.

[1]Department of Orthopaedic surgery, Dr. D.Y. Patil medical college, Nerul,Navi Mumbai.

Address of Correspondence
Dr. Arvind Janardhan Vatkar,
Department of Orthopaedic surgery, Dr. D.Y. Patil medical college, Nerul,Navi Mumbai.
Email: vatkararvind@gmail.com

Methods

We studied retrospective records of 4 cases of Type 4 Gartland type SHF. There was no neurovascular compromise in any of the cases studied. Only fractures showing intraoperative instability in flexion and extension under fluoroscopy were included in the study.

Surgical technique

We had positioned patient supine on OT table. Patient was given anesthesia. Patient's fractured arm was taken to the edge of the table. The steel OT table arm-rest was slided below the patient's chest for supporting the arm of patient. The pointed end came between the opposite axilla and chest. The fractured arm strapped to the end of side arm support with sticking tape(dynaplast) till mid-shaft humerus level, keeping the distal part of arm free as shown in the clinical picture.

The C arm is positioned parallel to the table. The arc of C arm is rotated to check Anteroposterior (AP) and lateral x ray

Figure 1: Positioning of patient with Side arm-rest strapped to mid arm level. C arm rotated to check reduction. Reduction maintained in 90 degree flexion.

shoots, instead of rotating the arm of patient. Rotating the child's arm to perform lateral imaging usually causes these fractures to lose reduction because of their high degree of instability [3].

Traction was applied to disengage the fragments of fractured humerus. Rotation, angulation and coronal (Varus/valgus) translation deformity were corrected by manipulation under AP X Ray guidance. This part of reduction was made easy because the proximal part of humerus was strapped to the side armrest. We needed to only manipulate the distal fragment to attain reduction in optimal position.The extension deformity was then corrected by flexing the elbow with forward pressure on the olecranon process, with use of lateral fluoroscopic imaging for guidance. At this stage, we confirmed intraoperatively that in such highly unstable fractures, the distal fragment goes in flexion as shown in figure 2 [5]. In this situation we extended the elbow till 90 degrees, and correct the translation

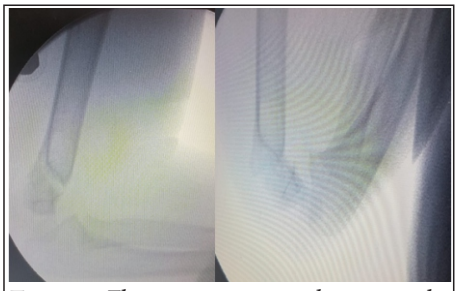

Figure 3: Fluoroscopy images showing multi directionally Unstable distal humerus fragment moving in flexion and extension.

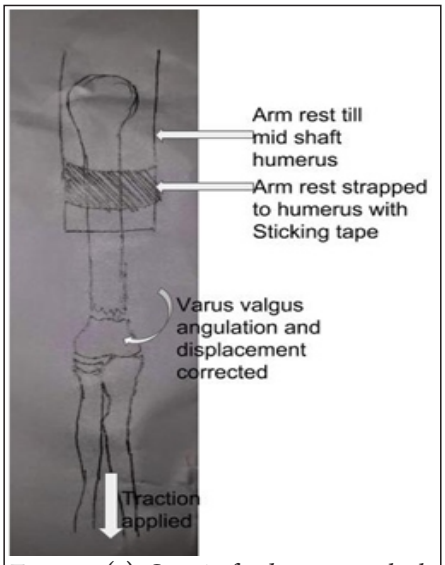

Figure 2 (a): Step 1 of reduction in which Traction is applied primarily. Later, Medio-lateral displacement and varus valgus angulation is corrected.

and angulation of distal fragment. Again AP x ray is taken to seen any displacement.

When reduction is achieved, the elbow should not be flexed completely as in conventional extension type of SCHF. Holding the hand to support the weight of limb suffices to maintain reduction and prevent posterior translation of distal fragment as shown in FIg 1. Oblique views were taken by rotating the C arm, to check for medial and lateral cortical continuity.

3 parallel K wires were put in standard fashion from lateral side, under C arm guidance.Medial pin was not deemed necessary. Generally the drill machine is hindered by the table in conventional method. But in our method, the distal end of humerus is free, thereby giving free maneuvering of drill machine to put K wires as shown in figure 3.

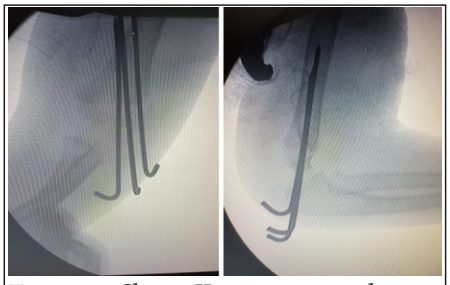

Figure 4: Shows K wire pinning done in Type 4 SCHF.

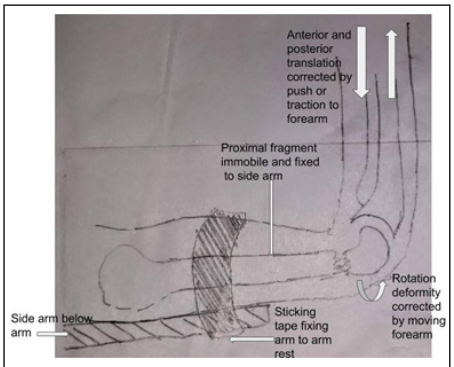

Figure 2 (b): Step 2 of reduction- Rotational deformity is corrected by movement of distal fragment of humerus. This is done by rotating only forearm, as proximal humeral shaft is strapped and fixed to side arm. Anterior-Posterior translation of distal humeral fragment is corrected by traction or push in direction parallel to the axis of forearm with elbow in 90 degrees.

Results

We studied the results of these 4 cases retrospectively based on their operative and clinical records. No immediate or late postoperative complication were noted in these cases. They were discharged on 3rd day postoperatively. Later they came for follow up on 4th week and 9th week. K Wires were removed on 4th week follow up visit. The ROM was was assessed at the 4th and 9th weeks. We saw excellent ROM and no varus deformity at the end of 9th week.

Discussion

Gartland et al had classified Extension type SHF, in to 3 types based on the degree of displacement. Type 1 SHF is undisplaced and Type 2 SHF is displaced with posterior cortex maintained. Gartland Type 3 SHF are with no cortical contact but with intact posterior periosteal hinge. This posterior hinge locks the reduced fracture fragments on flexion of elbow joint [3].

The technique we described has been detailed by Patwardhan et al in 2017. They used a wodden armboard with strapping of the arm to achieve the same result

Positive points of this technique

Table 1: Master chart of patient treated of Type 4 Gartland SHF.

	case 1	Case 2	Case 3	case 7
age	4 years	9 years	6 years	7 years
sex	male	Male	Female	male
open/close fracture	closed	Closed	Closed	closed
neurovascular status preoperatively	normal	Normal	Normal	normal
pin configuration	3 lateral pins	3 lateral pins	3 lateral pins	3 lateral pins
neurovascular status postoperatively	normal	Normal	Normal	normal
Range of motion at 4 weeks after pin removal	45-120 degrees	40-120 degrees	40-120 degrees	30-120 degrees
Range of motion at 8 weeks	0-130 degrees	0-140 degrees	0-120 degrees	0-140 degrees

1. The distal elbow region is free for mobilization of distal fragment while reducing the fracture
2. K wire pinning becomes simpler and drill machine is not hindered by arm-rest.
3. The proximal fragment of humerus fixed to the reversed armrest board. Hence, for correcting the rotational component of fracture, only distal fragment has to be manipulated.
4. Xray shoots on C arm are also clear as, the distal elbow region has no arm-rest below it, to hamper or distort X Ray view.
5. In multidirectional SC humerus fractures, the elbow can be kept in any degree of flexion position, to maintain the distal fragment aligned to proximal fragment.

Drawbacks of this technique

1. In case of very young children, the arm is very small compared to the standard width of the arm board. Hence strapping the arm becomes less effective.
2. The arm is fixed to the arm board. hence the arm cannot be manipulated to take lateral X Ray shoots. In such a scenario, the arc of C arm has to be rotated for taking lateral shoots.
3. We have done only 2 cases of multi-directionally unstable type 4 gartland SHF. It requires more cases establish this technique as an effective and easy method of treating Type 4 Gartland SHF.

Novais et al had studied 8 cases of Type 4 gartland SHF. They described a technique of using K wires as joystick and attaining reduction in Type 4 SHF. Despite surgical challenges, they got satisfactory results in their cases. An assistant would help to hold the arm and forearm to control the proximal and distal fragments of fractured humerus [5].

Leitch et al had published 9 cases of Type 4 Gartland SHF. The reduction was achieved by first inserting K wires into distal humeral fragment. Varus valgus deformity is corrected in Anteroposterior X Ray guidance. Later C arm arc is rotated for lateral X- ray Shoots. Flexion or extension deformity is corrected by flexing or extending elbow with anterior or posterior translation of distal fragment. Later Rotational deformity is corrected by pushing medial or lateral epicondyles. On attaining reduction, the partially inserted k wires are extended in proximal fragment and fixation achieved[3].

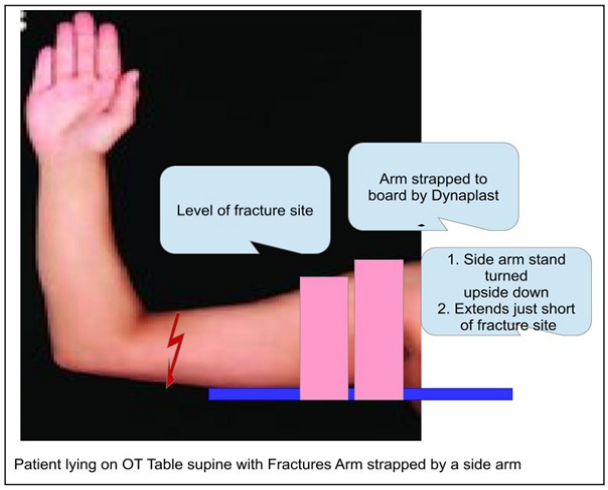

Patient lying on OT Table supine with Fractures Arm strapped by a side arm

Silva et al al had published series of 12 cases with such unstable SHF. In their technique, once coronal and anteroposterior translation is corrected, a rolled towel is kept below the arm, just proximal to the fracture site. Rotational deformity is corrected by rotating arm to control the proximal fragment. Distal humeral fragment is controlled by a K wire in joystick fashion. Then AP view alignment is corrected. Again 3 lateral entry pins are inserted in Lateral X Ray guidance. Lateral X Ray shoots are taken by rotating the arm, instead of rotating the arc of C arm [6].

Crossed pin configuration is advocated to have greater torsional stability than only lateral pins based on biomechanical studies.However, the use of 3 lateral-entry pins provided similar torsional rigidity to that achieved with cross pinning. But, if 3 lateral entry pins are used it provides equal amount of torsional stability of crossed pin configuration [7,8]. Lateral 3 pin configuration also preserves Ulnar nerve from iatrogenic injury while putting medial pins.

The lateral-entry pins offers the additional advantage of avoiding iatrogenic injury to the ulnar nerve. Brauer et al had reported through a systematic review of a high relative risk of 4.86 times with crossed pin configuration of pinning than lateral entry pin fixation [9]. Open reduction and fixation with k wires of such highly displaced fractures can give satisfactory reduction. But these are ridden with high rate of complications [10].

In summary, we conclude that our method can be used as an easy, reproducible and reliable method for closed reduction and pinning of Multi Directionally unstable SHF gratland type 4. THe key factors in our technique is adequately correcting the rotational deformity and antero posterior translation. Rotation of Arc of C arm instead of rotating arm to see AP and Lateral shoots, decreases the chances of

References

1. Alton, Timothy B., et al. "Classifications In Brief: The Gartland Classification of Supracondylar Humerus Fractures." Clinical Orthopaedics and Related Research®, vol. 473, no. 2, Jan. 2014, pp. 738–741., doi:10.1007/s11999-014-4033-8.
2. Shim, Jong Sup, and Won Hwan Oh. "Treatment of Supracondylar Fracture of the Humerus in Children: by Early Closed Reduction & K-Wire Fixation." Journal of the Korean Society of Fractures, vol. 11, no. 3, 1998, p. 634., doi:10.12671/jksf.1998.11.3.634.
3. Leitch, K. K., et al. "Treatment Of Multidirectionally Unstable Supracondylar Humeral Fractures In Children." The Journal of Bone and Joint Surgery-American Volume, vol. 88, no. 5, 2006, pp. 980–985., doi:10.2106/00004623-200605000-00008.
4. Kumar, Vineet, and Ajai Singh. "Fracture Supracondylar Humerus: A Review." Journal of Clinical and Diagnostic Research : JCDR 10.12 (2016): RE01–RE06. PMC. Web. 4 Sept. 2018.
5. The Use of a Joystick Technique Facilitates Closed Reduction and Percutaneous Fixation of Multidirectionally Unstable Supracondylar Humeral Fractures in Children - Eduardo Novais, Marco Andrade, Davi Gomes Journal of Pediatric Orthopaedics - / 2013
6. The Outcome of Surgical Treatment of Multidirectionally Unstable (Type IV) Pediatric Supracondylar Humerus Fractures - Mauricio Silva, Shannon Cooper, Angela Cha Journal of Pediatric Orthopaedics - 09 / 2015
7. Displaced Pediatric Supracondylar Humerus Fractures: Biomechanical Analysis of Percutaneous Pinning Techniques - Steven Lee, Andrew Mahar, Doug Miesen, Peter Newton Journal of Pediatric Orthopaedics - 07 / 2002
8. Torsional strength of pin configurations used to fix supracondylar fractures of the humerus in children. - L Zionts, H Mckellop, R Hathaway The Journal of Bone & Joint Surgery - 02 / 1994
9. A Systematic Review of Medial and Lateral Entry Pinning Versus Lateral Entry Pinning for Supracondylar Fractures of the Humerus - Carmen Brauer, Ben Lee, Donald Bae, Peter Waters, Mininder Kocher Journal of Pediatric Orthopaedics - 03 / 2007
10. Surgical management of the severely displaced supracondylar fracture of the humerus in children - Ritabh Kumar, E.krishna Kiran, Rajesh Malhotra, S Bhan

Conflict of Interest: NIL
Source of Support: NIL

How to Cite this Article

Vatkar A, Dhar S, Kale S, Bijlani N. A method of Patient positioning which aids in reduction of Multi-directionally unstable Gartland Type 4 fractures Supracondylar Humerus fracture with review of literature. Journal of Clinical Orthopaedics Jan-June 2019; 4(1):22-29