

# Thoughts on Anterior Cruciate Ligament Surgery over the Past 40 Years: Back to the Future

Chad Lasceski<sup>1</sup>, Chris Nacca<sup>1</sup>, Sarav S. Shah<sup>1</sup>, John C. Richmond<sup>2</sup>

## Abstract

Surgical treatment of anterior cruciate injury (ACL) has evolved over the last 40 years. Both patient as well as surgeon considerations must be made to optimize the successful treatment of an ACL injured patient. The focus of this paper is to discuss several of the many important issues that continue as topics of discussion in the literature and on the podium. These include graft selection and preparation, the role of anterior cruciate ligament repair, extra-articular tenodesis, and posterior tibial slope (PTS). We will present the current data as it pertains to these topics and include the senior author's preferences derived from 40 years of personal experience.

**Keywords:** ACL reconstruction, ACL repair, extra-articular tenodesis, ACL graft choice, posterior tibial slope

## Introduction

Anterior cruciate ligament tear (ACL) is one of the most common knee injuries. It is estimated there are between 100,000 and 200,000 ACL ruptures per year in the United States alone, with an annual incidence in the general population of approximately 1 in 3500 [1,2,3]. ACL deficiency leads to impairment of subjective and objective knee functional scores. The ACL primarily functions to limit anterior tibial translation. It also provides secondary rotational restraint [4]. Thus, ACL deficiency leads to both anteroposterior and rotational instability. This instability is a predisposing factor for meniscal and articular cartilage injury and degeneration [5].

ACL reconstruction improves knee stability and kinematics, and consequently patients have the potential to achieve higher functional scores approaching the ACL-intact knee. [6,7]. Data suggests that ACL reconstruction

can limit osteoarthritis development [8] and allows successful return to pivoting sporting activities [9].

Over the last 40 years, surgical treatment of ACL injuries has evolved. A myriad of factors must be considered including patient specific issues (associated injuries, timing of surgery, graft selection and preparation, and even bony anatomy) and physician specific considerations (surgical experience, teamwork, rehabilitation protocol). Successful ACL Reconstruction requires a high strength graft, anatomic positioning, rigid fixation, and avoiding problems along the way.

The focus of this paper is to discuss the avoidance of a number of complications in ACL surgery in light of the senior author's personal experience and thoughts throughout his career. These include: anterior knee pain from patella tendon autografts, inadequate diameter for hamstring autografts, reducing the risk of infection in ACL surgery, thoughts

on the resurgence of ACL repair, the potential role of lateral extra-articular augmentation in primary and/or revision ACL reconstruction, and the role of tibial slope in affecting ACL injury and surgical outcomes. This article reviews data as it pertains to ACL graft selection and preparation, reducing infection, anterior cruciate ligament repair, extra-articular augmentation, and the often-overlooked issues related to increased tibial slope.

## Graft Selection and Preparation

Graft selection is among the most debated topics regarding ACL reconstruction (ACLR). The 2 main alternatives used for grafts in ACL reconstruction are allografts and autografts. Hamstring and patellar tendon autografts (B-PT-B) are among the most common choices for reconstruction [10].

Anterior knee pain from patella tendon autograft harvest has been a recurring concern. However, many systematic reviews and meta-analyses confirm the value of B-PT-B Graft. When comparing revision surgery between hamstring and bone patellar tendon autografts, many studies appear to support the latter. Biau

<sup>1</sup>Department of Orthopedics 4th Floor 125 Parker Hill Avenue, Boston, MA 02120

<sup>2</sup>Department of Orthopedics Surgery 4th Floor 125 Parker Hill Avenue, Boston, MA 02120

### Address of Correspondence

Dr. John C. Richmond,

Department of Orthopedics Surgery 4th Floor 125 Parker Hill Avenue, Boston, MA 02120

E-mail: jr Richmond@nebh.org

et al. [11] demonstrated B-PT-B ACLR patients experienced less postoperative knee instability with a decreased risk of a positive pivot-shift test result compared with hamstring tendon autograft. In the Scandinavian ACL registries, most ACL reconstructions were performed using hamstring autograft (84%). However, in this data set, the overall risk of revision was significantly lower in the patellar tendon group versus the hamstring group. The lower risk of revision in the patellar tendon group was consistently observed across subgroups of patient sex, age, and concomitant cartilage injury [12]. The New Zealand ACL registry showed patients with a hamstring tendon graft had a revision rate of 2.7% compared with 1.3% in patients with a patellar tendon graft ( $p < .001$ ) [13]. Furthermore, the Multicenter Orthopaedic Outcomes Network (MOON) knee group most recently published an incidence of ACL graft revision at 6 years after index surgery was 2.1 times higher for high school and collegiate athletes with a hamstring autograft compared with a bone patellar tendon autograft [14].

Anterior knee pain is a major concern regarding bone-patellar tendon-bone autograft related to donor site morbidity [15]. This appears to occur in individuals that predominantly perform activities which involve kneeling. In order to mitigate the risk for anterior knee pain, we advocate for the following technique: preserve the patellar tendon paratenon/pre-patella bursa, harvest extra bone from tibia (which can be later used as bone graft for the patella), graft the patella defect prior to closing paratenon/pre-patella bursa, loosely close the patella tendon defect prior to closing paratenon, and close paratenon/pre-patella bursa. In the senior author's experience, using this sequence of steps has helped lower the risk of anterior knee pain.

One of the major concerns with hamstring autografts is graft diameter.

The MOON Cohort Study demonstrated graft diameter to be a significant predictor for the risk of failure. In their cohort, there was a 7% revision rate for grafts less than or equal to 8mm compared to 0% revision rate for grafts greater than 8mm. This appears to be an even more problematic issue when looking at the young active patient population (less than 18 years old). They found a 18.3% revision rate for these patients in the cohort with grafts less than or equal to 8mm compared to a 0% revision rate for those with grafts greater than 8mm [16]. As a result, 4,5, and 6-strand hamstring techniques been developed using shorter graft constructs which reliably give grafts  $\geq 8.5$ mm diameter, even for small females [17].

Overall, the decision of graft choice is multifactorial based patient age and activity level. An educated discussion should occur between surgeon and patient. Individualized treatment plans should occur. We recommend discussing with the patient potential differences in donor site morbidity, complication rates as well as objective and patient reported outcome measures when making an informed decision about graft selection. Overall, for patients under age 25, especially athletes participating in pivoting sporting activities, the senior surgeon prefers B-PT-B ACLR. Hamstring autografts are preferred in less aggressive athletes especially those over 25 years of age. There is a role for allografts in ACL reconstruction, but they should definitely be avoided in the young, pivoting sport athlete. The MOON group demonstrated that the odds of an ipsilateral ACL retear were 5.2 times greater for an allograft ( $P < 0.01$ ) than a B-PT-B autograft. That increased risk of retear decreased with age, such that by the age of 40, there was no increased retear rate for allografts and they are an attractive alternative for many patients over 40 who are not at high risk from aggressive cutting or pivoting sports [18].

It is important to include reduction of the risk of infection from ACL surgery in the discussion of preparation of all ACL grafts. Infection following ACL reconstruction may range from 1-2%, and can have disastrous consequences, leading to repeated surgeries [19,20]. Naykayama et al have demonstrated that there were significant numbers of grafts (2%) and skin at incision sites (6%) that were contaminated coagulase negative *Staphylococcus* sp., which were often methicillin resistant [21]. Both Vertullo et al and Baron et al have used dilute vancomycin to soak their grafts prior to implantation and demonstrated a 10-fold reduction in infection rates from 1.4% to 0% in Vertullo's study and 1.2% to 0.1% in Baron's study [19,20]. We encourage and routinely use antibiotic soaking while the graft is under tension on the back table and irrigate the wound with antibiotics as the graft is delivered into the knee.

### Anterior Cruciate Ligament Repair

ACL injuries were first described and diagnosed in military cadets based on physical exam as outlined by Feagin et al [22]. Sixty-four cadets underwent open arthrotomy and primary repair of the ACL based on exam. Initially, the Feagin et al group demonstrated good or excellent 2 year-follow-up; however, at 5 years, over 50% had failed ACL repairs based on physical exam [23,24]. They concluded that "an injury to the anterior cruciate ligament is a compromising event even when subjected to repair." [22]. In their 30-year on average follow-up study, Taylor et al demonstrated a mix of both acceptable and unacceptable outcomes with mirroring the 5-year data [24]. Kaplan et al. also studied a group of 52 patients who underwent primary repair with an average follow-up of 6 years. They had an overall 17% failure rate and 42% of patients had abnormal laxity on KT-1000 testing [25]. These findings demonstrate that primary repair can be successful in a subset of patients;

however, long term results are not acceptable. This highlights the importance of longer-term follow-up in order to truly evaluate the efficacy of ACL primary repair.

As arthroscopic techniques have evolved, ACL repair more recently has been revisited. Jonkergouw et al [26]. reported 56 arthroscopic suture anchor-based repairs of proximal tears with a portion of these having suture augmentation. Repairs were only performed in proximal ACL tears with both enough remnant ligament length and adequate tissue quality as determined by the senior author. Six repairs failed (10.7%) within 1 year. There was no difference between those with and without suture augmentation. Overall, patient reported outcomes were significantly improved but no return to sport data was collected. The failure rate was higher than reported for ACLR, however there is the advantage of no donor site morbidity [26]. The same group sought out to identify which subset of patients would most benefit from repair given more selective criteria when considering repairs. Surprisingly, out of 365 patients, in 158 patients (44%) primary repair was possible. Multivariate analysis demonstrated that age > 35, surgery within 28 days, and BMI < 26 were predictive for the possibility of repair. Lateral meniscus injury decreased the likelihood for repair. They did not look at outcomes in this study [27]. A recent systematic review by Nwachukwu et al. also evaluated outcomes following primary surgical repair of ACL tears [28]. The studies included utilized both primary suture repair and dynamic intra-ligamentary stabilization. For all types or ACL repairs overall, re-ruptures were as high as 23.1%, revision surgery 33.3%, and overall reoperations 51.5%. With a subgroup analysis of just proximal tear repairs the rates of revision ACLR and total reoperations were as high as 12.9% and 18.2%, respectively [28]. As demonstrated in previous studies

proximal repairs have the best chance for success, however the rate of failure is still higher than traditional ACL reconstruction.

Apart from the anatomical factors implicated in ACL repair, biologic augmentation has more recently been an expanding area of interest and research. Current research is also focused on regulating the extracellular matrix turnover to allow for ligament development and repair following injury [29]. A collagen-based, bridge-enhanced scaffold with fibroblasts present can synthesize ten-fold more collagen compared with fibroblasts on culture plates [30]. This collagen scaffold seems to offset the natural biologic effects of the synovial environment. The current scaffold being utilized in the bridge-enhanced anterior cruciate ligament repair (BEAR) trial was developed by Martha Murray M.D. and her research team at Boston's Children's Hospital. It is a bovine collagen scaffold soaked with whole blood [31]. The hypothesized advantages of bridge enhanced ACL repair include: (1) blood cells added to the scaffold may have an anti-inflammatory effect by releasing chondroprotective cytokines, (2) the proprioceptive function is restored through repair because the torn ends of the ACL (with their proprioceptive abilities) are maintained, and (3) the collagen bridge itself may prevent the degradative enzymes from degrading the articular cartilage.

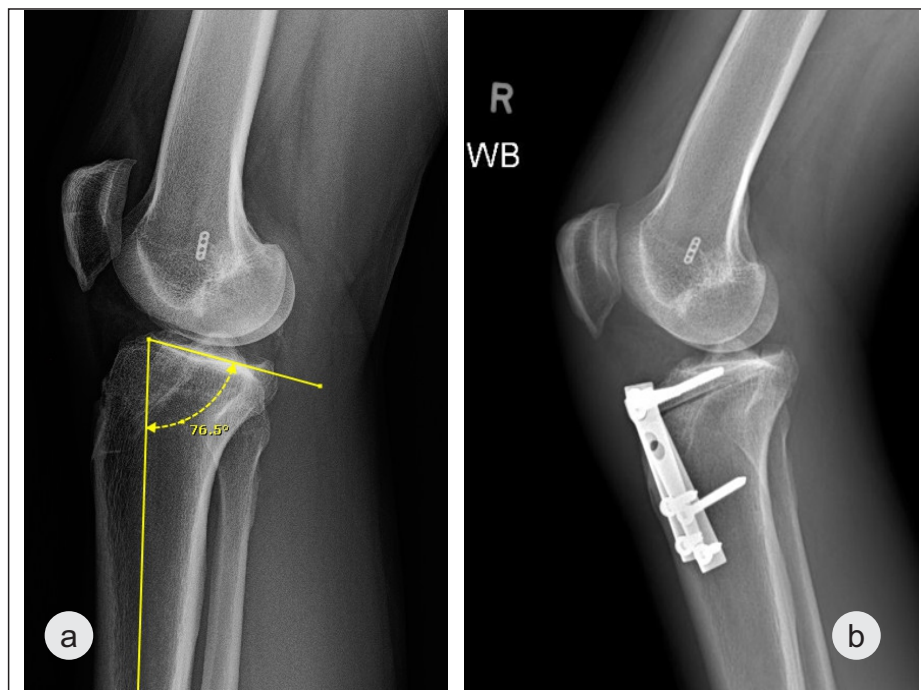
The BEAR trial has published results after 2 years in 10 patients compared to patients who received a 4-strand hamstring autograft. Patients included were ages 18-35 with isolated full thickness mid-substance ACL tears. Bucket-handle meniscus tears were excluded from these cohorts. Overall, results were excellent in both groups with no failures at 2 years. Functional and subjective outcome scores demonstrated no significant differences [31]. There are 2 clinical trials of the BEAR technique

currently listed on the United States National Institutes of Health as of March 2020 (<https://clinicaltrials.gov/ct2/show/NC T03776162> and <https://clinicaltrials.gov/ct2/show/NC T02664545>). Although neither is recruiting study subjects today, we look forward to their results. Certainly, it is too early to make definitive conclusions; however, the search for the ideal growth factors and/or stem cells to augment the scaffold is likely a significant area of research focus.

### Extra-articular Augmentation

The anterolateral ligament of the knee is believed to have been first described by Paul Segond in 1879. Segond described a “pearly, resistant, fibrous band which invariably showed extreme amounts of tension during forced internal rotation (of the knee)” at the location of what is now referred to as a “Segond fracture.” [32]. Hughston and Andrews in 1976, provided the blueprint for the detailed anatomy that comprises the lateral aspect of the knee. In their classification of knee ligament instabilities, they described a disruption of the mid third of the lateral capsule resulting in anterolateral rotatory instability [33]. Claes et al in 2013 rediscovered the “mid- third” lateral capsule and renamed it the anterolateral ligament (ALL) [34].

Song et al [35], in their systematic review, investigated clinical outcomes of combined lateral extra-articular tenodesis (LET) and intra-articular ACL reconstruction (ACLR) in treating ACL injuries with high-grade pivot shift. Among the 5 comparative studies, the prevalence of residual pivot shift was significantly lower in patients with LET plus ACLR (13.3%) than those with isolated ACLR (27.2%). Although LET plus ACLR provided a significant reduction in the prevalence of residual pivot shift, there was no differences in objective International Knee Documentation Committee (IKDC)



**Figure 1a:** Lateral knee radiograph of a 25-year-old male who has torn 2 ACL autograft reconstructions and has undergone a resection of the majority of his medial meniscus. His posterior tibial slope is  $>13^\circ$ .

**Figure 1b:** Immediate post-operative lateral radiograph following a deflexion osteotomy, with bone grafting his tunnels, which reduced his PTS to  $4^\circ$ . The revision ACL reconstruction with medial meniscal transplantation was performed as a 2nd staged procedure.

scores and anterior knee stability compared with isolated ACLR at short-term follow-up (mean 46.2 months, range 24-76 months).

Isolated extra-articular reconstructions are rarely performed in contemporary practice. If done in isolation, they are associated with a high rate of persistent anterior instability and early degenerative change. Combined ACLR and LET results in a significant reduction in the prevalence of residual pivot shift, but most of the studies do not demonstrate any significant difference with respect to patient-reported outcome measures and return to sport. Early on some authors reported a trend towards decreased graft rupture rates[31], and more recent literature has been able to elucidate a significant clinical decrease in rupture rates. In a clinical study, combined anatomic ACL and ALL reconstruction was reported to be associated with a threefold reduction

in graft rupture rates and improved return to sport compared to isolated ACL graft choices[37]. Getgood et al, in a recent randomized controlled trial, demonstrated the addition of LET to a single-bundle hamstring tendon autograft ACLR in young patients at high risk of failure resulted in a statistically significant, clinically relevant reduction in graft rupture and with reduced rotatory laxity at 2 years after surgery [38].

The senior author's preferred technique is similar to that described by Ferreira et al, with placement of the reconstruction deep to the lateral collateral ligament. [39]. While the absolute indications for LET have not yet been defined consideration should be given in those patients undergoing primary surgery with a grade 3 pivot shift and when a Second fracture is present with any degree of pivot shift. Perhaps the clearest indication for an extra-articular

augmentation is in patients requiring revision surgery who have a grade 3 pivot after a previously well-performed ACL reconstruction when no additional reason for failure is identified, It is important not to over-constrain the knee, with an emphasis to tension in full extension and neutral rotation.

### Considerations on Tibial Slope

Over the last decade increased posterior tibial slope (PTS) has been identified as one of the factors that increases the risk of ACL tearing and also increases the risk of failure of ACL reconstruction[40,41]. Posterior tibial slope has a direct effect on ACL loading and in the active population at the United States Military Academy at West Point Todd et al demonstrated that in cadets with noncontact ACL tears had significantly greater PTS ( $9.39^\circ \pm 2.58^\circ$ ) than did non-injured control subjects ( $8.50^\circ \pm 2.67^\circ$ )[40]. Webb et al studied a cohort of 200 consecutive ACL patients that underwent 1<sup>o</sup> using hamstring autografts which were part of their prospective longitudinal ACL study[41]. Of the 181 patients that had complete follow-up data, 50 went on to tear either their ACL graft or the ACL in their contralateral knee. The 50 patients with further ACL injury had a PTS of  $9.9^\circ$  versus  $8.5^\circ$  for the 131 patients without further injury ( $P = .001$ ). For those patients who tore both their ACL graft and their contralateral ACL the mean PTS was  $12.9^\circ$ . In those patients with PTS  $\geq 12$  the odds of further ACL injury was increased by a factor of 5, approaching 60%. Based on this data, I measure tibial slope off a lateral radiograph on every ACL injured patient and counsel my patients and their families that a PTS  $\geq 10^\circ$  is a concern and  $\geq 12^\circ$  might be a reason to consider an alternative athletic career.

Correction of an elevated tibial slope is an alternative in those patients elevated PTS who have failed prior ACL reconstruction. (Figure 1) Dejour et al have reported on successful outcomes in

repeated ACL revision reconstruction by performing a deflexion osteotomy with the repeat revision ACL reconstruction[42]. In their series of 10 patients with 90% follow-up at a minimum of 2 years (range 2.5 to 8.0 years) they lowered the mean PTS from  $13.2^{\circ} \pm 2.6^{\circ}$  preoperatively to  $4.4^{\circ} \pm 2.4^{\circ}$  and all patients remained stable.

## Conclusion

As surgeons, we need to continue to learn from the past while also not being the

first or last to adapt to innovation. ACL repair is a great example in which early results in the past were good but with time, its effectiveness fell off. Albeit, repair has come back around in terms of proximal repairs and now biologic scaffold augmentation with early promising results. Successful ACL reconstruction requires a high strength graft, anatomic tunnel positioning, and rigid fixation. Continued prospective collection of patient data will be important moving forward as we attempt

to further help guide our decisions in ACL reconstruction or repair to provide the best care to our patients. In summary, the lessons learned in the past 40 years for a successful ACL surgery include: 1. High strength graft with meticulous harvest and preparation, 2. Anatomic positioning, 3. Rigid fixation, 4. Avoiding problems along the way, 5. Learning from past missteps, and 6. Don't be the 1st or last to adopt what's new. Always be driven by science and doing what is best for your patients.

## References

- Gordon MD, Steiner ME. Anterior cruciate ligament injuries. In: Orthopaedic Knowledge Update Sports Medicine III, Garrick JG (Ed), American Academy of Orthopaedic Surgeons, Rosemont 2004. p.169
- Albright JC, Carpenter JE, Graf BK, et al. Knee and leg: soft tissue trauma. In: Orthopaedic Knowledge Update 6, Beatty JH (Ed), American Academy of Orthopaedic Surgeons, Rosemont 1999. p.533
- Miyasaka KC, Daniel DM, Stone ML. The incidence of knee ligament injuries in the general population. *Am J Knee Surg.* 1991;4:43.
- Markolf KL, Mensch JS, Amstutz HC. Stiffness and laxity of the knee--the contributions of the supporting structures. A quantitative in vitro study. *J Bone Joint Surg Am.* 1976;58(5):583-94.
- Daniel DM, Stone ML, Dobson BE, et al. Fate of the ACL-injured patient. A prospective outcome study. *Am J Sports Med.* 1994;22(5):632-644.
- Georgoulis AD, Ristanis S, Moraiti CO, et al. ACL injury and reconstruction: Clinical related in vivo biomechanics. *Orthop Traumatol Surg Res.* 2010;96(8 Suppl):S119-S128.
- Loh JC, Fukuda Y, Tsuda E, et al. Knee stability and graft function following anterior cruciate ligament reconstruction: Comparison between 11 o'clock and 10 o'clock femoral tunnel placement. 2002 Richard O'Connor Award paper. *Arthroscopy.* 2003;19(3):297-304
- Ajuied A, Wong F, Smith C, et al. Anterior cruciate ligament injury and radiologic progression of knee osteoarthritis: a systematic review and meta-analysis. *Am J Sports Med.* 2014;42(9):2242-2252.
- Øiestad BE, Holm I, Risberg MA. Return to pivoting sport after ACL reconstruction: association with osteoarthritis and knee function at the 15-year follow-up. *Br J Sports Med.* 2018;52(18):1199-1204.
- Goldblatt J.P., Fitzsimmons S.E., Balk E., Richmond J.C. Reconstruction of the anterior cruciate ligament: Meta-analysis of patellar tendon versus hamstring tendon autograft. *Arthroscopy.* 2005;21:791-803.
- Biau DJ, Katsahian S, Kartus J, et al. Patellar tendon versus hamstring tendon autografts for reconstructing the anterior cruciate ligament: a meta-analysis based on individual patient data. *Am J Sports Med.* 2009;37(12):2470-2478.
- Gifstad T, Foss OA, Engebretsen L, et al. Lower risk of revision with patellar tendon autografts compared with hamstring autografts: a registry study based on 45,998 primary ACL reconstructions in Scandinavia. *Am J Sports Med.* 2014;42(10):2319-2328.
- Rahardja R, Zhu M, Love H, Clatworthy MG, Monk AP, Young SW. Effect of graft choice on revision and contralateral anterior cruciate ligament reconstruction: Results from the New Zealand ACL Registry. *Am J Sports Med.* 2020;48(1):63-69.
- MOON Knee Group, Spindler KP, Huston LJ, et al. Anterior cruciate ligament reconstruction in high school and college-aged athletes: Does autograft choice influence anterior cruciate ligament revision rates? *Am J Sports Med.* 2020;48(2):298-309.
- Chee MY, Chen Y, Pearce CJ, et al. Outcome of patellar tendon versus 4-strand hamstring tendon autografts for anterior cruciate ligament reconstruction: A systematic review and meta-analysis of prospective randomized trials. *Arthroscopy.* 2017;33(2):450-463.
- Mariscalco MW, Flanigan DC, Mitchell J, Pedroza AD, Jones MH, Andrish JT, Parker RD, Kaeding CC, Magnussen RA. The influence of hamstring autograft size on patient-reported outcomes and risk of revision after anterior cruciate ligament reconstruction: A Multicenter Orthopaedic Outcomes Network (MOON) Cohort Study. *Arthroscopy.* 2013 Dec;29(12):1948-53.
- Figueroa F, Figueroa, Espregueira-Mendes J. Hamstring autograft size importance in anterior cruciate ligament repair surgery. *EFORT Open Rev* 2018;3:93-97.
- Kaeding CC, Pedroza AD, Reinke EK, et al. Risk factors and predictors of subsequent ACL injury in either knee after ACL reconstruction: Prospective analysis of 2488 primary ACL reconstructions from the MOON cohort. *Am J Sports Med.* 2015;43(7):1583-1590.
- Vertullo CJ, Quick M, Jones A, Grayson JE. A surgical technique using presoaked vancomycin hamstring grafts to decrease the risk of infection after anterior cruciate ligament reconstruction. *Arthroscopy.* 2012;28(3):337-342.
- Baron JE, Shamrock AG, Cates WT, Cates RA, An Q, Wolf BR, et al. Graft preparation with intraoperative vancomycin decreases infection after ACL reconstruction. *J Bone Joint Surg Am.* 2019;101(24):2187-2193.
- Nakayama H, Yagi M, Yoshiya S, Takesue Y. Micro-organism colonization and intra-operative contamination in patients undergoing arthroscopic anterior cruciate ligament reconstruction. *Arthroscopy.* 2012;28(5):667-671.
- Feagin JA, Abbott HG, Rokous JA. The isolated tear of the anterior cruciate ligament. *J Bone Joint Surg Am.* 1972;54(6):1340-1341.

23. Feagin JA, Curl WW. Isolated tear of the anterior cruciate ligament: 5-year follow-up study. *Am J Sports Med* 1976;4(3):95-100.
24. Taylor DC, Posner M, Curl WW, Feagin JA. Isolated tears of the anterior cruciate ligament. Over 30-year follow-up of patients treated with arthroscopy and primary repair. *Am J Sports Med*. 2009;37(1):65-71.
25. Kaplan N, Wickiewicz TL, Warren RF. Primary surgical treatment of anterior cruciate ligament ruptures. A long-term follow-up study. *Am J Sports Med*. 1990;18(4):354-358.
26. Jonkergouw A, Van der List JP, DiFelice GS. Arthroscopic primary repair of proximal anterior cruciate ligament tears: outcomes of the first 56 consecutive patients and the role of additional internal bracing. *Knee Surg Sports Traumatol Arthrosc* 2019 Jan; 27(1):21-28.
27. Van der List JP, Jonkergouw A, van Noort A, Kerkhoffs GMMJ, DiFelice GS. Identifying candidates for arthroscopic primary repair of the anterior cruciate ligament: A case-control study. *Knee*. 2019 Jun;26(3):619-627
28. Nwachukwu BU, Patel BH, Allen AA, Williams RJ. Anterior cruciate ligament repair outcomes: An updated systematic review of recent literature. *Arthroscopy*. 2019 July;35(7)2233-2247.
29. Waryasz GR, Marcaccio S, Gil JA, Owens BD, Fadale PD. Anterior cruciate ligament repair and biologic innovations. *J B J S R e v . 2 0 1 7 ; 5 ( 5 )* : <http://dx.doi.org/10.2106/JBJS.RVW.16.00050>
30. Dunn MG, Liesch JB, Tiku ML, Zawadsky JP. Development of fibroblast-seeded ligament analogs for ACL reconstruction. *J Biomed Mater Res*. 1995;29(11):1363-1371.
31. Murray MM, Kalish LA, Fleming BC, et al. Bridge-enhanced anterior cruciate ligament repair: Two-year results of a first-in-human study. *Ortho J Sports Med*. 2019;7(3):1-13.
32. Segond P. Recherches cliniques et expérimentales sur les épanchements sanguins du genou par entorse. *Progrès Médical* 1879; 16: 297–299, 319–321, 340–341
33. Hughston JC, Andrews JR, Cross MJ, Moschi A. Classification of knee ligament instabilities. Part II. The lateral compartment. *J Bone Joint Surg Am*. 1976;58(2):173–179.
34. Claes S, Vereecke E, Maes M, Victor J, Verdonk P, Bellemans J. Anatomy of the anterolateral ligament of the knee. *J Anat*. 2013;223(4):321–328. doi:10.1111/joa.12087
35. Song GY, Hong L, Zhang H, Zhang J, et al. Clinical outcomes of combined lateral extra-articular tenodesis and intra-articular anterior cruciate ligament reconstruction in addressing high-grade pivot-shift phenomenon. *Arthroscopy*. 2016;32(5):898–905.
36. Sonnery-Cottet B, Barbosa NC, Vieira TD, Saithna A. Clinical outcomes of extra-articular tenodesis/anterolateral reconstruction in the ACL injured knee. *Knee Surg Sports Traumatol Arthrosc*. 2018;26(2):596–604.
37. Sonnery-Cottet B, Saithna A, Frois Temponi E, et al. Anterolateral ligament reconstruction is associated with significantly reduced ACL graft rupture rates at a minimum follow-up of 2 years: A prospective comparative study of 502 patients from the SANTI study group. *Am J Sports Med*. 2017;45(7):1547-1557.
38. Getgood AMJ, Bryant DM, Litchfield R, et al. Lateral extra-articular tenodesis reduces failure of hamstring tendon autograft anterior cruciate ligament reconstruction: 2-year outcomes from the STABILITY study randomized clinical trial. *Am J Sports Med*. 2020;48(2):285–297.
39. Ferreira Mde C, Zidan FF, Miduati FB, et al. Reconstruction of anterior cruciate ligament and anterolateral ligament using interlinked hamstrings - technical note. *Rev Bras Ortop*. 2016;51(4):466–470.
40. Todd MS, Laliss S, Garcia E, et al. The relationship between posterior tibial slope and anterior cruciate ligament injuries. *Am J Sports Med*. 2010;38(1):63-67.
41. Webb JM, Salmon LJ, Leclerc E, Pinczewski LA, et al. Posterior tibial slope and further anterior cruciate ligament injuries in the anterior cruciate ligament-reconstructed patient. *Am J Sports Med*. 2013;41(12):2800-2804.
42. Dejour D, Saffarini M, Demey G, Baverel L. Tibial slope correction combined with second revision ACL produces good knee stability and prevents graft rupture. *Knee Surg Sports Traumatol Arthrosc*. 2015;23(10):2846-2852.

**Conflict of Interest: NIL**  
**Source of Support: NIL**

#### How to Cite this Article

Lasceski C, Nacca C, Shah SS, Richmond JC. Thoughts on Anterior Cruciate Ligament Surgery over the Past 40 Years: Back to the Future. *Journal of Clinical Orthopaedics* Jan-Jun 2020;5(1):15-20.