

# When All Is Not Good – Managing an Adolescent with Osgood–Schlatter Disease

Tushar Agarwal<sup>1</sup>, Pooja Suratwala<sup>2</sup>

## Abstract

Anterior knee pain in children above 10 years of age is a part of every orthopaedic surgeon OPD practice. Osgood-Schlatter disease is the most common cause in skeletal or immature athletic children. It is a condition, in which the patellar tendon insertion on the tibial tuberosity becomes inflamed. It tends to occur more commonly in boys and it occurs in the second decade of life (10-15 years). It is a self-limiting condition and occurs secondary to repetitive extensor mechanism stress activities such as jumping and sprinting. OSD is a clinical diagnosis, and only radiographic evaluation may be done to confirm the diagnosis. Pain level dictates overall treatment, and management includes symptomatic treatment with ice and NSAIDs, as well as activity modification. & relative rest from inciting activities in association with lower extremities stretching exercises. In this paper we discuss the etiology, presentation, evaluation, and management of Osgood Schlatter disease.

**Keywords:** Osgood Schlatter disease, osteochondritis, anterior knee pain

## Introduction

Anterior knee pain in children above 10 years of age is a part of every orthopaedic surgeon OPD practice. If this pain is at the level of tibial tuberosity, then we all tend to diagnose it as Osgood–Schlatter disease (OSD). We all tend to conserve these, most respond, and some may not resolve and move on to someone else for an opinion. Let's see if there are any new pointers that we can offer in this article to help our patient's better.

The main concerns in the child's and their parent's minds are can we continue to play and will we have to change our sport. Let's try to answer these questions here.

OSD, also called Lannelongue's disease is a condition, in which the patellar tendon insertion on the tibial tuberosity becomes inflamed.

It is a well-known condition in late childhood characterised by pain over the tibial tuberosity along with a bony prominence.

Usually, it resolves at the end stages of skeletal growth. Boys are affected more often than girls, and the age of affection is typically in the second decade of life (10–15 years in boys and 8–12 years in girls) (Fig. 1). Usually, <25% of patients complain of pain over the tibial tuberosity. In the early stages of OSD, the patients have pain in the tibial tuberosity after physical activities, but over time, the pain becomes permanent and steady regardless of activity.

In X-rays, a regular ossification (ossicle) is demonstrated over the tibial tuberosity.

Treatment includes conservative and surgical options. Conservative treatment

includes modifying physical activities, using ice packs, non-steroidal anti-inflammatory drugs (NSAIDs), braces, and pads. Symptoms usually resolve after the closure of the physis without any treatment, but symptoms may remain in some cases.

In almost 10% of patients, the bone fragments do not fuse, and these patients complain of pain in front of the knee, even after slight physical activity but especially after kneeling. This pain typically relates to the mobile and unfused bone fragments, which may require surgical excision [1].

## A Representative Case

An 8–15-year-old child will typically present with anterior knee pain with or without swelling which can be unilateral or bilateral.

Pain begins as a dull ache localised over the tibial tubercle gradually increasing with activity. The presentation is typical of insidious onset without preceding trauma. Pain typically improves with rest and will subside minutes to hours after the inciting activity or sport is stopped.

<sup>1</sup>Aastha Hospital, 65 Balasinar Society, SV Road Kandivali West, Mumbai 67 India,

<sup>2</sup>Clinical Fellow Paediatric Orthopaedics, Aastha Hospital, Kandivali, India.

## Address of Correspondence

Dr. Tushar Agrawal, Aastha Hospital, 65 Balasinar Society, SV Road Kandivali West, Mumbai 67, India.

E-mail: drtusharagrawal@gmail.com

Submitted Date: 27 Apr 2023, Review Date: 18 May 2023, Accepted Date: 02 Jun 2023 & Published Date: 30 Jun 2023

© Journal of Clinical Orthopaedics | Available on [www.jcorth.com](http://www.jcorth.com) | DOI:10.13107/jcorth.2023.v08i01.557

This is an open access journal, and articles are distributed under the terms of the Creative Commons Attribution-NonCommercial-ShareAlike 4.0 License (<https://creativecommons.org/licenses/by-nc-sa/4.0/>), which allows others to remix, tweak, and build upon the work non-commercially, as long as appropriate credit is given and the new creations are licensed under the identical terms.

Condition	Signs/symptoms	Investigations
Fracture of tibial tuberosity	A history of trauma is present, the onset of symptoms is sudden, and the patient is not able to extend the knee or bear weight on the knee.	An irregular line is present on x-ray without fragmentation of tibial tuberosity.
Hoffa's disease (Fat pad hypertrophy/impingement)	Tenderness in the anterior joint line lateral to the patellar tendon.	X-ray is normal in Hoffa's disease.
Sinding-Larsen and Johansson syndrome (Inferior patellar pole traction apophysitis)	Maximal tenderness is at the inferior pole of the patella, not at the tibial tubercle.	On x-ray, the tibial tuberosity is normal, and an ossicle or osteophyte in the lower pole of the patella is present.
Infrapatellar bursitis	It is difficult to differentiate infrapatellar bursitis from OSD clinically; the location of pain is at or near the attachment of the patellar tendon to the tibial tuberosity, but there may be no tenderness when palpating the tibial tuberosity.	X-ray is normal or may show a soft tissue swelling. In MRI, tibial tuberosity is normal, but it shows the fluid collection in the infrapatellar region.
Osteomyelitis	Pain may be present with activity or rest, and systemic symptoms and signs of infection are present.	In blood exam, there are increased levels of ESR, CRP, and WBC. Blood culture is positive, and soft tissue swelling periosteal reaction are seen in x-ray.
Osteochondritis dissecans of the knee	Pain is located in the anterior or anteromedial aspect of the knee. Tenderness is localized to the joint line (usually medial), with no tenderness on tibial tuberosity.	The lesion is apparent via x-ray in the lateral aspect of the medial femoral condyle. Otherwise, an MRI is needed for diagnosis.
Patellar tendonitis	It is difficult to differentiate from OSD, and may occur as a complication of OSD.	Radiographic studies are normal or may show a soft tissue swelling. Tibial tuberosity appears normal in MRI or may show increased signal in the patellar tendon.
Chondromalacia patella (runner's knee)	Pain is present in the knee region (patellofemoral pain). On examination, pain becomes apparent with pressure on patella or manipulating patella above femoral condyle [14]. A grinding or cracking feel is present during extension and flexion of the knee joint.	In the radiographic study, there may be bone damage, or signs of arthritis seen. MRI will reveal any cartilage damage.

TABLE 1: Table showing the differential diagnosis of OSD

Pain is exacerbated particularly by running, jumping, direct knee trauma, kneeling, and squatting.

An enlarged prominence at the tibial tubercle is present with tenderness over the site of patellar tendon insertion.

Poor flexibility of the quadriceps and

hamstrings may be present as predisposing factors.

Pain may be reproduced by resisted knee extension and active or passive knee flexion [2].

### Historical Aspect

The language of orthopaedics is rather interesting in that it often credits the original describers or those who popularised a disease process by attaching their names to the disease process in question.

These so-called “eponyms” have become commonplace in our literature and offer an important orthopaedic historical insight.

Often throughout history simultaneous discovery of a disorder is described by two independent researchers, resulting in a hyphenated eponym.

Such is the case in the observations made by two physicians, Robert Bayley Osgood and Carl Schlatter, concerning overuse injuries of the tibial tubercle in adolescents.

This disorder became famous as “OSD.”

Radiography was first discovered in 1895 and Robert Osgood took a keen interest in the orthopaedic applications of this tool at the Boston Children's Hospital.

He was an eminent Professor of Orthopaedics in North America, contributing actively to academics and training for many years. He served as deputy to Major General Sir Robert Jones in England and trained numerous American orthopaedic surgeons in treating war casualties.

Carl Schlatter was from Zurich and worked extensively in Vienna. He too was interested in war casualties and trauma and was very active academically.

Osgood published his observations on

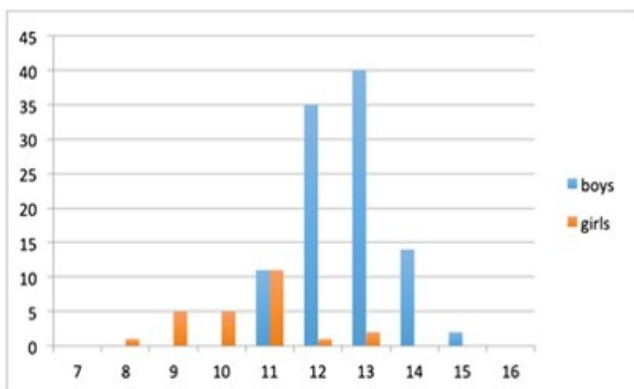


Figure 1: Male-female incidence [4]

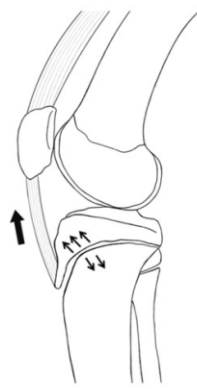


Figure 2: Impact of increased posterior slope.

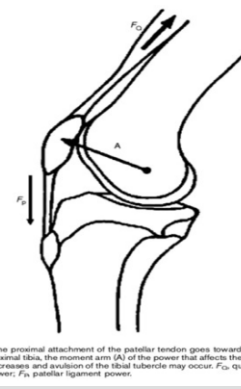
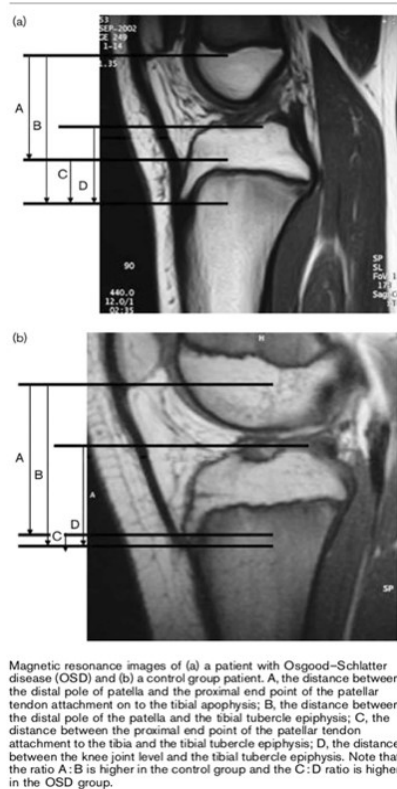

Figure 3: Impact of shorter and broader insertion of patellar tendon [8].

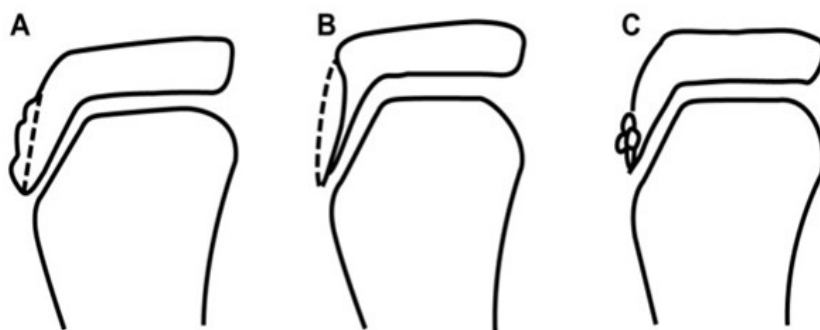


**Figure 4:** Shorter broader and more proximal insertion of patellar tendon [8].

ten cases of tibial tubercle apophysitis. He stated, “Sudden strain of the quadriceps extensor partially ruptures the cartilaginous union of the tongue like prolongation of the upper epiphysis of the separate ossification center... Subsequent exercises of any kind and sometimes the ordinary walking pull of the quadriceps irritates the injured cartilage and gives rise to discomfort until advice is sought or bony union at length takes place.”

Osgood thought that surgery was ill-advised and a conservative treatment of 6–8 weeks of immobilization restored function, even though the fragment is not restored to its old position.

Schlatter made a similar observation of seven cases previously incorrectly diagnosed as tuberculosis. He wrote, “that these injuries represent a clinically sharply delineated profile of the disease, whose symptom complex is in most cases simple and easy to interpret without radiographic assistance.”



The severity of Osgood-Schlatter disease in the epiphyseal stage on radiographic findings. (A) Grade I, upheaval or slight elevation of the tibial tuberosity; (B) grade II, radiolucency of the tibial tuberosity; (C) grade III, fragmentation of the tibial tuberosity.

**Figure 5:** X-ray severity of Osgood-Schlatter

It is interesting to note that neither the diagnosis nor the treatment has essentially changed much in this disease over the past 100 years since it was first described [3].

### The Pathophysiology of Osgood-Schlatter

OSD is an overuse injury that occurs in active adolescent patients.

It occurs secondary to repetitive strain and microtrauma from the force applied by the strong patellar tendon at its insertion into the relatively soft apophysis of the tibial tubercle. This force results in irritation and severe cases partial avulsion of the tibial tubercle apophysis.

Force is increased with higher levels of activity and especially after periods of rapid growth. Rarely, trauma may lead to a full avulsion fracture.

Predisposing factors include poor flexibility of quadriceps and hamstrings or other evidence of extensor mechanism misalignment.

Risk factors for the disorder include:

- Male gender
- Ages: male 12–15, girls 8–12
- Sudden skeletal growth
- Repetitive activities such as jumping and sprinting.

### Multiple Theories Proposed

1. Avulsion of a portion of tibial

tuberosity secondary to contraction of the quadriceps muscle

2. Detachment of either bony or cartilaginous portions of ossification center from tuberosity. Once detached, cartilage or bone is susceptible to chronic motion and localized painful nonunion

3. Localized tendonitis

4. Bursa between ossicle and tibial tuberosity

5. Tendinous insult, bony avulsion fracture, or both associated cartilage thickening. This thickening contributes to the anterior deformity seen

6. Patella alta

7. Patella baja

8. Rectus contracture (Fig. 2)

9. Genu valgus, pronated feet, and anteversion of femur with lateral tibial torsion

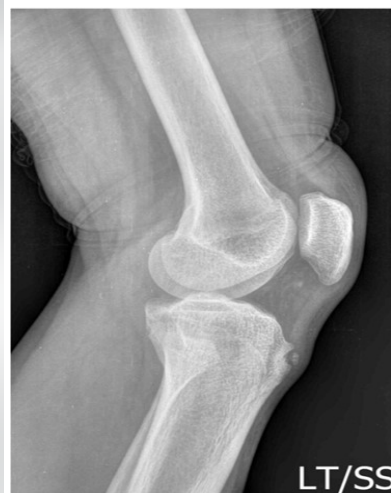10. A higher patellar position would increase the force transmitted onto the tibial tuberosity

11. Patellar tendon attaches more proximally and over a broader area [6, 7]. (Fig. 3,4)

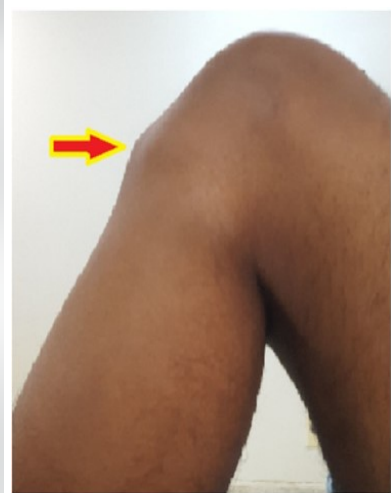### Common Sports Seen in Association with the Condition Include

1. Basketball
2. Volleyball
3. Sprinters
4. Gymnastics
5. Football
6. Cricket.





**Figure 6:** Lateral X-ray showing tibial tuberosity prominence and ossicle [1]



**Figure 7:** Clinical image showing lateral prominence [1].

### Clinical Presentation

It classically associates atraumatic, insidious onset of anterior knee pain, with tenderness at the patellar tendon insertion site at the tibial tuberosity/bony prominence (Fig. 7).

The condition is self-limited and occurs secondary to repetitive extensor mechanism stress activities such as jumping and sprinting.

Pain level dictates overall treatment, and management includes symptomatic treatment with ice and NSAIDs, as well as activity modification and relative rest from inciting activities in association with lower extremities stretching regimen to correct underlying predisposing biomechanical factors.

the disorder is gradual and commonly associated with repetitive activities of the knee. There is usually tenderness over the tibial tubercle.

### Evaluation

OSD is a clinical diagnosis, and radiographic evaluation is usually not necessary.

Plain radiographs may be used to rule out additional diagnoses such as fracture, infection, or bone tumour if the presentation is severe or atypical.

The radiographic evaluation may also be indicated to evaluate for avulsion injury of the apophysis or other injuries after a traumatic event.

Even though the disorder is benign, the recovery can be prolonged and cause absence from sports. The onset of

represent pathology, so clinical correlation is of utmost importance.

If ordering radiographs consider comparing bilateral images to delineate normal versus abnormal in the individual patient.

The high-frequency ultrasonogram (USG) could depict pathological changes in soft tissues and could play a pivotal role in differentiating OSD from other anterior knee pain disorders.

USG can detect every pathological change concerning OSD, including cartilage swelling, fragmentation of the tuberosity ossification center, patellar tendon lesions, and reactive bursitis; and based on these USG findings, it could be of three types: type 1, delamination of the internal ossification center; type 2, delamination tear or fracture of the epiphyseal part of the tibial tuberosity; and type 3, delamination tear of the ossification center resulting in an irregular deformation of the tuberosity.

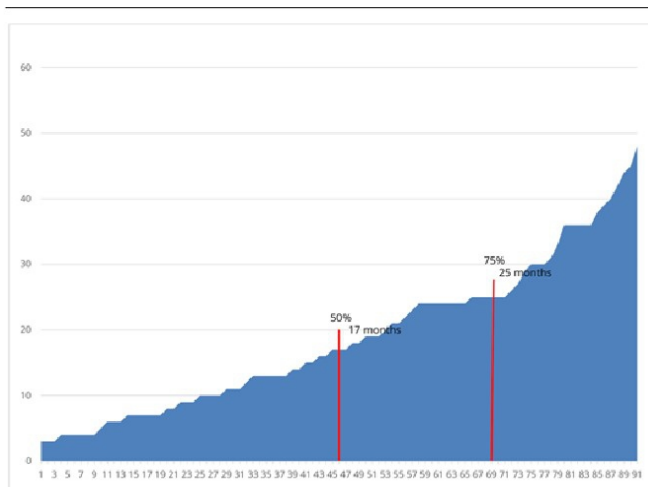
However, in the disorder, USG may reveal a normal tubercle, and signal changes consistent with thickening (more echogenic) in the patellar tendon, as seen in MRI, could be the only presenting sign.

Ultrasonographic scanning has also the potential of differentiating OSD from jumper's knee and Sinding-Larsen-Johansson syndrome.

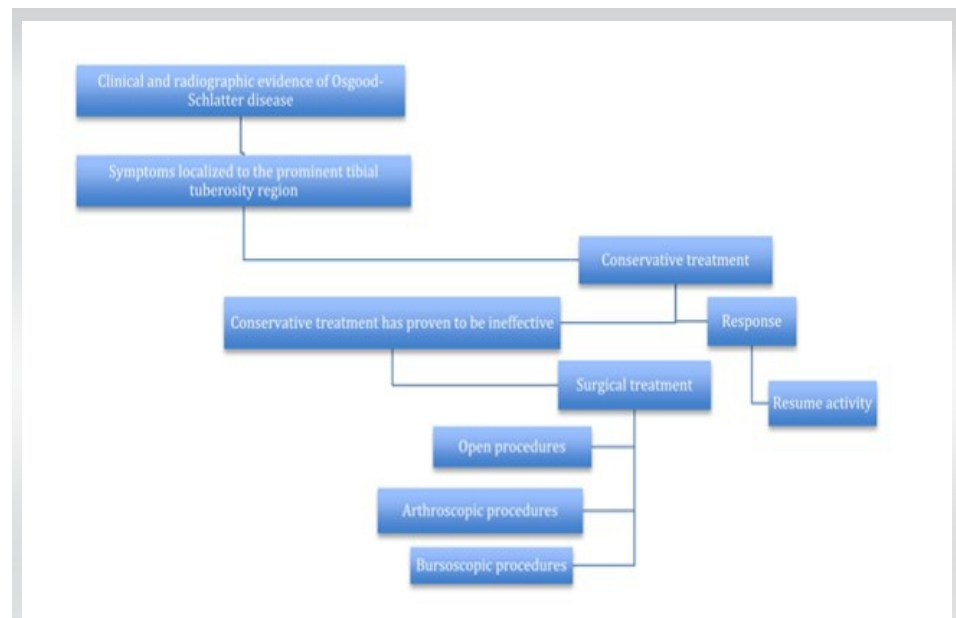
In a recent meta-analysis, USG has been reported to have the potential of predicting future tendinopathy even in asymptomatic individuals [9].

In young adults with OSD, the MRI revealed a relatively less free portion and relatively more proximal attachment of the patellar tendon compared to those of young adults without OSD. Furthermore, positive correlations were found between the free portion of the patellar tendon and the clinical scores in the OSD patients. In future research, a detailed analysis of the patellar tendon attachment should be conducted since secondary patellar tendinopathy is also

Classic radiographic findings in OSD include an elevated tibial tubercle with soft-tissue swelling, fragmentation of the apophysis, or calcification in the distal patellar tendon (Fig. 5,6). It is worth noting that these findings can also be seen as normal variants and do not always



**Figure 8:** Percentage recovery over time [4].



**Figure 9:** Algorithm for treatment of Osgood-Schlatter [14].

frequently encountered in patients with OSD [7].

Computed tomography (CT) scans seem to have a limited role, mainly in identifying the separate ossicle which may lead to persistent symptoms after skeletal maturity.

CT scanning is not routinely performed, but it may be helpful in skeletally mature patients where additional pathological conditions are being considered or in rare cases in which complication may not be detectable with plain radiographs like the presence of a physeal bar that may lead to tibia recurvatum or the presence of a small, painful, and unfused ossicle.

### Differential Diagnosis

There are some other diseases that should be considered in the differential diagnosis of OSD, such as Sinding-Larsen-Johansson syndrome, Hoffa's syndrome, soft tissue or bone tumors, patellar tendon avulsion or rupture, chondromalacia patella, patellar tendinitis, infectious apophysitis, accessory ossification centers, osteomyelitis of the proximal tibia, and tibial tubercle fracture. (Table 1)

### Treatment

The primary goal in the treatment of OSD

is the reduction of pain and swelling over the tibial tuberosity. The patient should limit physical activities until the symptoms are resolved. In some cases, the patient should restrict physical activities for several months. The presence of pain with kneeling due to an ossicle that does not respond to conservative measures is an indication for surgery. In these cases, the removal of the ossicle, surrounding bursa, and the bony prominence is the treatment of choice.

The treatment of OSD is based on the severity of the symptoms.

It is a self-limiting disease and most commonly resolves with skeletal maturity. This correlates with the closure of the apophysis.

### Conservative

The standard first line of treatment is conservative.

In the acute phase, initial treatment includes ice application, infrapatellar strap, pads, or brace. Short-term rest and knee immobilization. In severe cases, a brief period of controlled immobilization for 6 weeks may help. Long-term immobilization is contraindicated as it may result in knee stiffness.

Once the acute symptoms have abated, hamstrings and quadriceps flexibility

exercises help by reducing the tension on the tibial tubercle and may accelerate the recovery. Restriction of or a change in sports activities such as swimming or cycling helps in maintaining knee range of motion and it may accelerate recovery.

NSAIDs when given for a short period of time help decrease prostaglandin synthesis and have analgesic/ antipyretic and anti-inflammatory effects. However, NSAIDs have not been shown to shorten the course of the disease [10].

### Injection

Patellar tendon insertion corticosteroid injections have not been recommended due to the possibility of subcutaneous tissue atrophy and rupture of the patellar tendon.

Small-needle injection of the patellar tendon enthesis/tibial apophysis with 12.5% dextrose is safe and well tolerated in adolescents with recalcitrant OSD.

Repair of soft tissue such as ligament and cartilage is accomplished by regenerative polypeptides, called growth factors, which are produced locally. Growth factors require sustained glucose metabolism to promote cell survival, and glucose cannot be transported into the cell without transporter proteins that are stimulated by growth factors. Genes for growth factor production are activated within 20 min of human cell exposure to 0.45% glucose.

Topol et al. concluded that the duration of sports-related symptoms could be reduced by dextrose injection than either lidocaine injection or usual care in those with recalcitrant OSD [11].

### Surgical Management

Although conservative management has been conventionally favored,

surgical intervention can be successful for patients who have intolerable symptoms. Surgery is rarely indicated in skeletally immature patients as removal of ossicle fragmentation with an unfused apophysis leads to premature fusion of the tibial tubercle.

According to a study conducted by Trail, surgery was found to offer no significant benefit over conservative care in skeletally immature patients.

Surgical management is indicated in adults with continued symptoms.

Surgical procedures consist of drilling of the tubercle, removal of loose fragments, tibial tuberosity excision or sequestrectomy, and autogenous bone peg insertion. Surgical management can be approached by open, arthroscopic, or baroscopic.

Tibial prominence resection and ossicle excision are the most commonly done OPD procedures. Tibial prominence resection is indicated in adults with recalcitrant cases. Ossicle excision is indicated in patients who are refractory to conservative treatment, with clinically evident mobile ossicles and the presence of a free osseous fragment on X-ray [12]. The arthroscopic approach has been recommended in recent years as it is a less invasive procedure, and it does not involve a direct incision over the patellar

tendon which leads to pain postoperatively.

Arthroscopy [13] is performed through the standard low anterolateral and anteromedial portals close to the patellar tendon. The ossicle is separated from the surrounding soft tissue with a motorized shaver and radiofrequency device and removed by use of a grasper. After the excision of the ossicle, the inflamed surface of the retro-patellar tendon is debrided. The irregular surface of the tibial tubercle is contoured with the help of a burr.

The arthroscopic approach can violate the intra-articular infrapatellar fat pad during the excision of the ossicle.

Recently, the bursoscopic [14] excision technique has been introduced as it is shown to minimize the infrapatellar fat pad violation.

Other surgical procedures, such as autogenous bone peg insertion or drilling the tuberosity, have not been recommended as it promotes early fusion of the apophysis of the tuberosity to the diaphysis [15]. (Fig. 9)

### Rehabilitation Following Surgical Management

Rehabilitation consists of the use of a hinged knee brace locked in extension and full weight-bearing. Early passive

knee range of motion is allowed. Weight-bearing in extension is mandatory for the first 3–4 weeks if tendon healing to bone is needed. Straight-leg raises can be initiated immediately after surgery. Once tendon healing is complete, usually between 4 and 6 weeks, active range of motion and strengthening are allowed [1, 2, 15, 16, 17]. (Fig. 8)

### Summary

1. There is more than one diagnosis of anterior knee pain in children
2. Sports is a trigger point for getting anterior knee pain
3. OSD is pain on tibial tuberosity, numerous theories to explain the pain
4. X-rays are the mainstay, but now USG and MRI have a role in diagnosis and prognostication.
5. Almost all will respond to conservative treatment
6. Surgery if at all is indicated only after skeletal maturity
7. Change in the type of sport helps in overcoming pain.
8. Hamstring strengthening and rectus stretches are important.

**Declaration of patient consent:** The authors certify that they have obtained all appropriate patient consent forms. In the form, the patient has given the consent for his/ her images and other clinical information to be reported in the journal. The patient understands that his/ her names and initials will not be published and due efforts will be made to conceal their identity, but anonymity cannot be guaranteed.

**Conflict of interest:** Nil **Source of support:** None

## References

1. Vaishya R, Azizi AT, Agarwal AK, Vijay V. Apophysitis of the tibial tuberosity (Osgood-Schlatter disease): A review. *Cureus* 2016;8:e780.
2. Ladenhauf HN, Seitlinger G, Green DW. Osgood-Schlatter disease: A 2020 update of a common knee condition in children. *Curr Opin Pediatr* 2020;32:107-12.
3. Nowinski RJ, Mehlman CT. Hyphenated history-Osgood-Schlatter disease. *Am J Orthop (Belle Mead NJ)* 1998;27:584-5.
4. Gaulrapp H, Nührenbörger C. The Osgood-Schlatter disease: A large clinical series with evaluation of risk factors, natural course, and outcomes. *Int Orthop* 2022;46:197-204.
5. Green DW, Sidharthan S, Schlichte LM, Aitchison AH, Mintz DN. Increased posterior tibial slope in patients with Osgood-Schlatter disease: A new association. *Am J Sports Med* 2020;48:642-6.
6. Uzunov V. A look at the pathophysiology and rehabilitation of Osgood-Schlatter Syndrome. *Gym Coach* 2008;2:39-45.

7. Demirag B, Ozturk C, Yazici Z, Sarisozen B. The pathophysiology of Osgood-Schlatter disease: A magnetic resonance investigation. *J Pediatr Orthop B* 2004;13:379-82.
8. Kadirhan O, Fatihoglu E. Magnetic resonance imaging findings in Osgood Schlatter disease: A case report. *Curr Res MRI* 2022;1:50-1.
9. Siddiq MA. Osgood-Schlatter disease unveiled under high-frequency ultrasonogram. *Cureus* 2018;10:e3411.
10. Neuhaus C, Appenzeller-Herzog C, Faude O. A systematic review on conservative treatment options for OSGOOD-Schlatter disease. *Phys Ther Sport* 2021;49:178-87.
11. Topol GA, Podesta LA, Reeves KD, Raya MF, Fullerton BD, Yeh HW. Hyperosmolar dextrose injection for recalcitrant Osgood-Schlatter disease. *Pediatrics* 2011;128:e1121-8.
12. Weiss JM, Jordan SS, Andersen JS, Lee BM, Kocher M. Surgical treatment of unresolved Osgood-Schlatter disease: Ossicle resection with tibial tubercleplasty. *J Pediatr Orthop* 2007;27:844-7.
13. Tsakotos G, Flevas DA, Sasalos GG, Benakis L, Tokis AV. Osgood-Schlatter lesion removed arthroscopically in an adult patient. *Cureus* 2020;12:e7362.
14. Fujita K, Nakase J, Yoshimizu R, Kimura M, Kanayama T, Tsuchiya H. Bursoscopic ultrasound-guided ossicle resection for Osgood-Schlatter disease. *Arthrosc Tech* 2022;11:e841-6.
15. Pihlajamäki HK, Mattila VM, Parviainen M, Kiuru MJ, Visuri TI. Long-term outcome after surgical treatment of unresolved Osgood-Schlatter disease in young men. *J Bone Joint Surg Am* 2009;91:2350-8.
16. Circi E, Atalay Y, Beyzadeoglu T. Treatment of Osgood-Schlatter disease: Review of the literature. *Musculoskelet Surg* 2017;101:195-200.
17. Corbi F, Matas S, Álvarez-Herms J, Sitko S, Baiget E, Reverter-Masia J, et al. Osgood-Schlatter disease: Appearance, diagnosis and treatment: A narrative review. *Healthcare (Basel)* 2022;10:1011.

**Conflict of Interest: NIL**  
**Source of Support: NIL**

#### How to Cite this Article

Agarwal T, Suratwala P. When All Is Not Good – Managing an Adolescent with Osgood–Schlatter Disease. *Journal of Clinical Orthopaedics* Jan-June 2023;8(1):28-34.